

MammoVision (Active Functional Infrared Breast Thermography) Compared to X-Ray Mammography - 114 Cases Evaluated

Reinhold Berz and Claus Schulte-Uebbing

Prof. Reinhold Berz, MD

President

German Society of Thermography and Regulation Medicine (DGTR)

DGTR office

Rheinstrasse 7

D-76337 Waldbronn

Prof. Claus Schulte-Uebbing, MD

Gynecology Oncology Immunology, Endocrinology, Environmental Medicine

Weinstr. 7a,

D-80333 Munich

Table of Contents

- 1 Introduction
 - 1.1 Breast Metabolism and Heat Signs
 - 1.2 Infrared Thermography
- 2 MammoVision Methodology of Active Thermography (Functional IR Imaging)
 - 2.1 MammoVision Equipment
 - 2.2 MammoVision Evaluation Guideline
- 3 Patients Examined
- 4 Results
 - 4.1 Illustrations of BIRAS Classified Results
 - 4.2 Statistical Results
- 5 Conclusion
- 6 Abbreviations

1 Introduction

Breast cancer is the leading deadly cancer in women at least in the developed countries. X-ray mammography (MG) is called the gold standard for detecting breast cancer, but the method has some limitations: For many women MG may be painful, and the ionizing radiation could cause malignancy. More importantly: Cancerous lumps must have a diameter of at least 5 mm (often much more) to be detected by MG. Many breast cancers at this stage are 5 to 10 years old. Earlier detection is requested, but seems to be not easy to do by the established methods. MRI could be a better way, but there is a lack of experience, and it is costly. Ultrasonography (USG) can be helpful, too, but is recognized as a complementary examination.

1.1 Breast metabolism and heat signs

There is a well known relationship between breast cancer and breast heat signs. Especially aggressive and fast growing breast cancers have an exaggerated metabolism causing a high blood supply. Intraoperative studies have demonstrated that breast cancer leads to an increased venous flow and to heat convection [1]. Usually the healthy breast is, depending on its size, colder than the surrounding chest and abdominal areas without thermographically visible signs of vessels or hot spots. Both breasts should have an average temperature differing not more than 0,5 °C (thermal symmetry, Fig. 1).

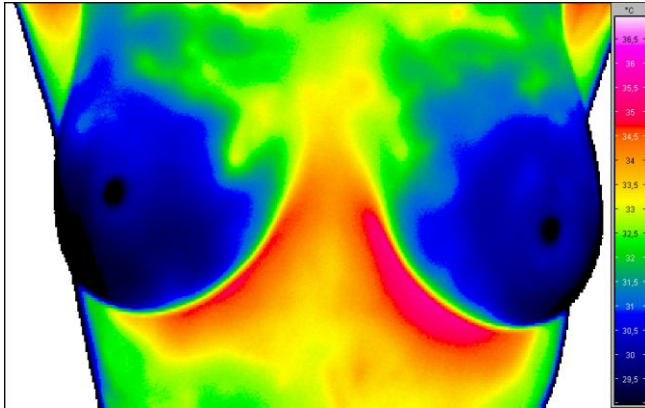


Figure 1: Normal MammoVision result of a 29-year-old healthy woman: symmetrically cool, no visible vessels, no hot spots, nipple and areola cold, contour without bulge or edge sign.

1.2 Infrared thermography

The heat patterns of the breasts can be recorded with infrared detecting devices (infrared cameras), that have been in use for medical purposes since 1956 [2-5]. Since the late 1990s, due to the technological progress and sensor development, infrared imaging devices are much more suitable for medical measurements [6]. According to PLANCK's law, the infrared radiation of the human skin of 30 °C (303 K) peaks at a wavelength of about 10 µm, and so called long wave infrared cameras (LWIR) are suitable to record and measure the heat pattern of the breast (Fig. 2). Comparable to the US FDA approval, in Europe medical temperature measurement devices have to comply with the Medical Devices Directive, Council Directive 93/42 [7]. This approval regards the whole equipment: IR camera, cable connections, power supply, computer and other hardware, software and examination rack.



Figure 2: Medically approved infrared camera Jenoptik (formerly Carl Zeiss Jena) VarioCam Head

2 MammoVision Methodology of Active Functional Thermography

There are different approaches to conduct infrared thermography of the female breast. To solve the problem of lacking standardization, the method of Active Functional Thermography, with decades of applications, was chosen. This approach is based on the idea that the response to a stimulus (like in other medical examinations, e.g. ECG or EEG) enhances the diagnostic value and acuteness. Active Functional Thermography applies a cool air stress

exposure to the patient (disrobed at room temperature of 19 to 21 °C) and measures the thermal pattern immediately after disrobing (comfort temperature) and a second time after adapting to the cold ambient (temperature decrease after 10 minutes) [8-15]. This method has shown to be appropriate for female breast imaging [16]. For other applications different cold stress tests are common [17-19]. The reaction to the cooling stimulus leads to a skin temperature decrease of about 1,0 °C within the breast areas (Fig. 3).

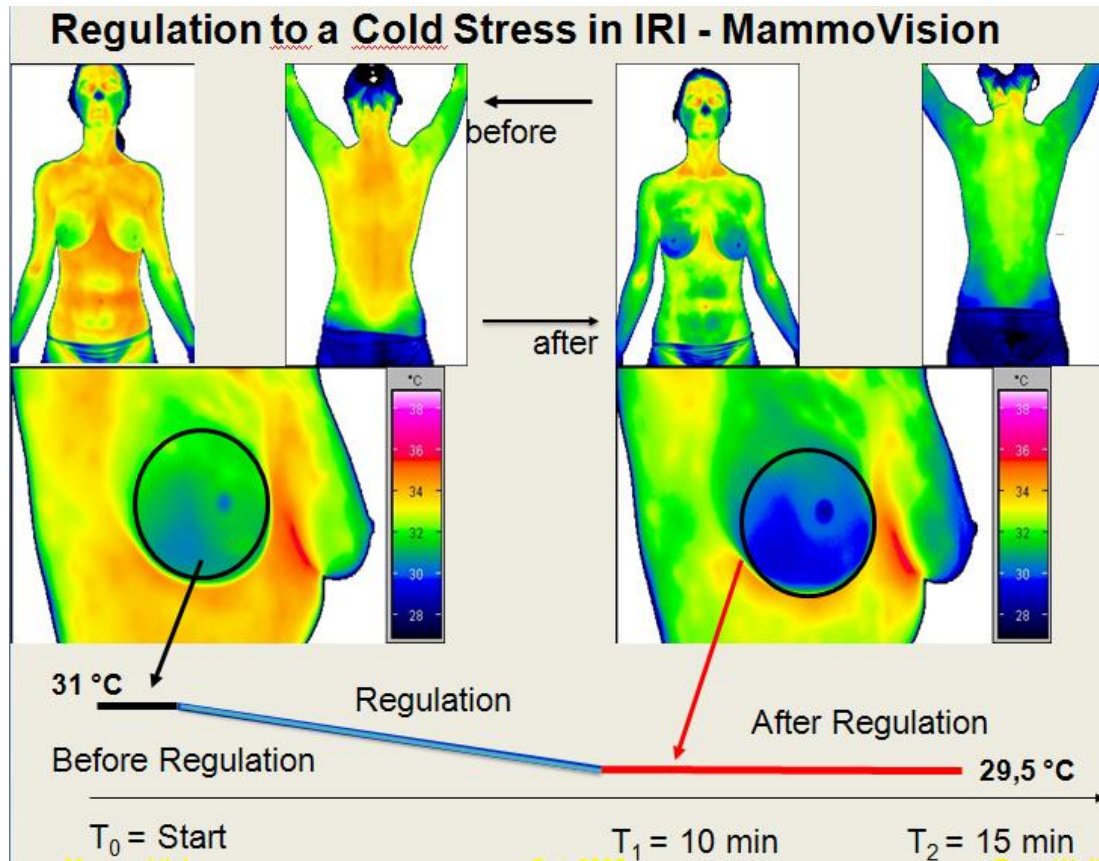


Figure 3: Principles of IRI (Infrared Regulation Imaging) and MammoVision

Very important is the appropriate preparation of the patient, the adaptation to the examination room (patient dressed and in thermal balance) of 30 minutes, the ambient conditions of the examination room (19-21 °C, humidity between 30 and 50 %, no direct sunshine or other high thermal gradients within the room). An early prototype and recent MammoVision equipment are shown in Figure 4.

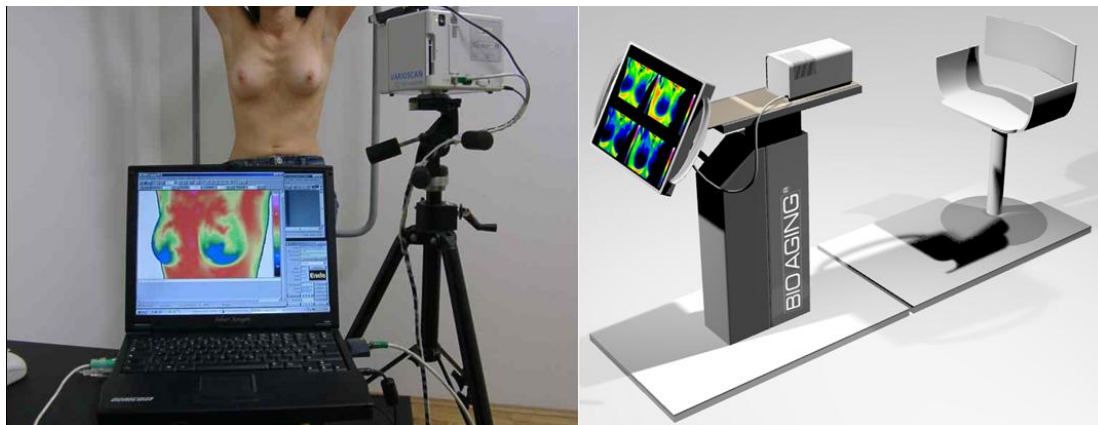


Figure 4: Early prototype of MammoVision (2000, left) and recent MammoVision device (bioaging Stuttgart, Germany, right)

2.1 MammoVision equipment

MammoVision requires a complete medically approved temperature measurement system. The IR camera used for this study was a German made Jenoptik (formerly Carl Zeiss Jena) VarioCam Head with a spatial resolution of 320x240 sensors, detector pitch 35 x 35 μm , sensitivity 60 mK and better, accuracy $\pm 0,4$ $^{\circ}\text{C}$, stability over time 20 min after onset better than $\pm 0,5$ $^{\circ}\text{C}$, lens aperture $f=1,0$, focal length $f=25$ mm. An additional digital camera (webcam) takes a colour picture in parallel for the documentation of scarves or other visible breast abnormalities.

Core of the MammoVision system is the medically approved software EXAM for administration, examination, measurement and imaging control, data storage and, most importantly, data evaluation, and generating a medical report [20].

2.2 MammoVision evaluation guideline

The MammoVision examination needs 10 images: 5 before and 5 after temperature decrease due to the cooling. The patented equipment and procedure [21] ensures that the views are more or less identical, which is important for the evaluation (Fig. 5).

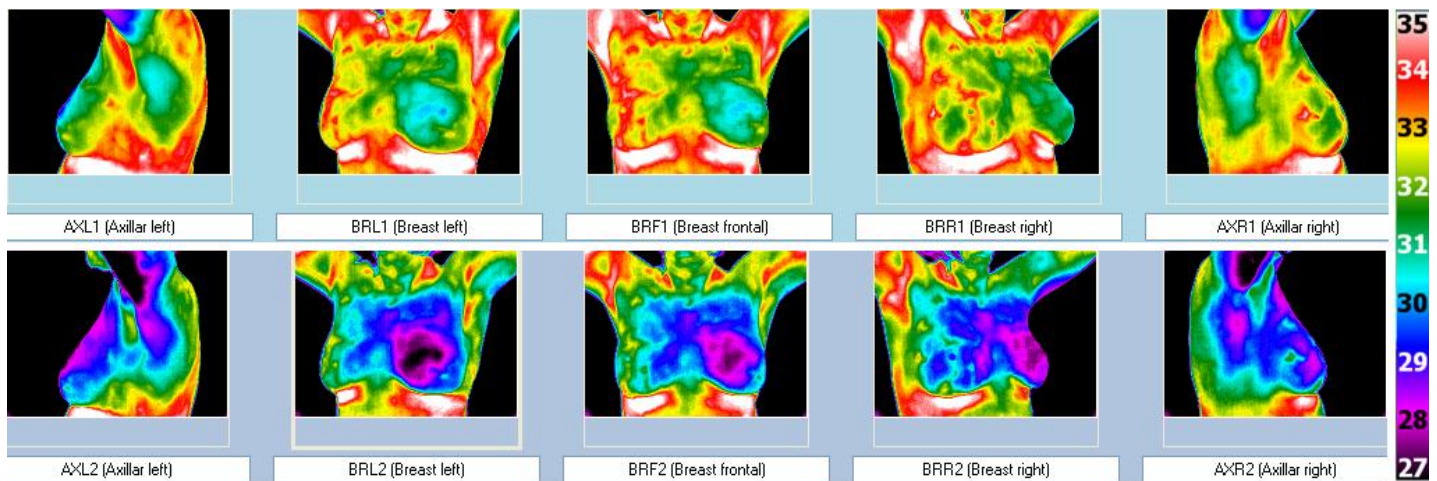


Figure 5: Measurement views of MammoVision: upper row before cold stimulus, lower row after cold stimulus and cooling down

After recording the measurement and images, the evaluation process starts: A patented evaluation procedure [22] including a grid system marks the breast areas that will be mathematically evaluated. This grid should cover the same breast areas of the images taken before and after the cooling stimulus (Fig. 6 left side). The most important evaluation criteria in (Fig. 6 right side) cover a) the thermal lateral symmetry between both breasts; b) the isothermia (span between minimum and maximum temperature) within the four quadrants of each breast (superior lateral, inferior lateral, inferior medial, and superior medial); c) the areolar temperature; d) the nipple temperature; e) the temperature decrease after the cooling stimulus (down regulation); and f) the hotspot parameter [23].

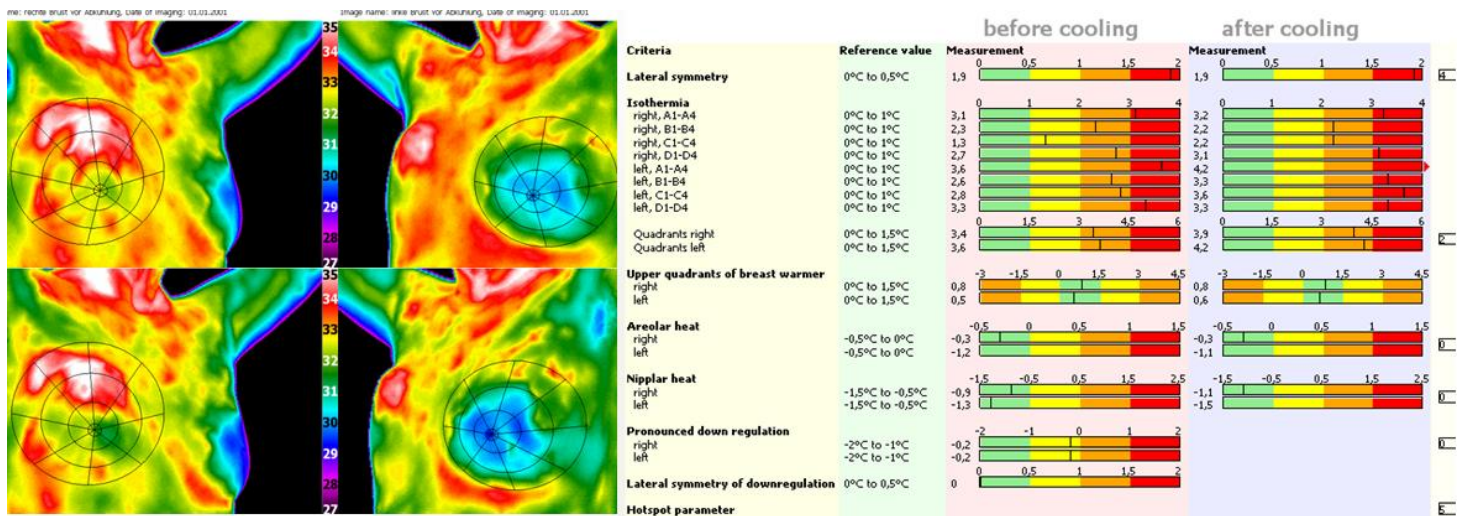


Figure 6: Positioning of the evaluation grid in MammoVision (left): upper row before, lower row after cold stimulus and cooling (woman with hot cancer in the right breast); MammoVision results in an evaluation graph (right)

The next step demands a detailed description of the vascular situation (a grayscale image is more suitable than a colour masked one, Fig. 7). The shapes of the breasts and vascular signs have to be assessed.

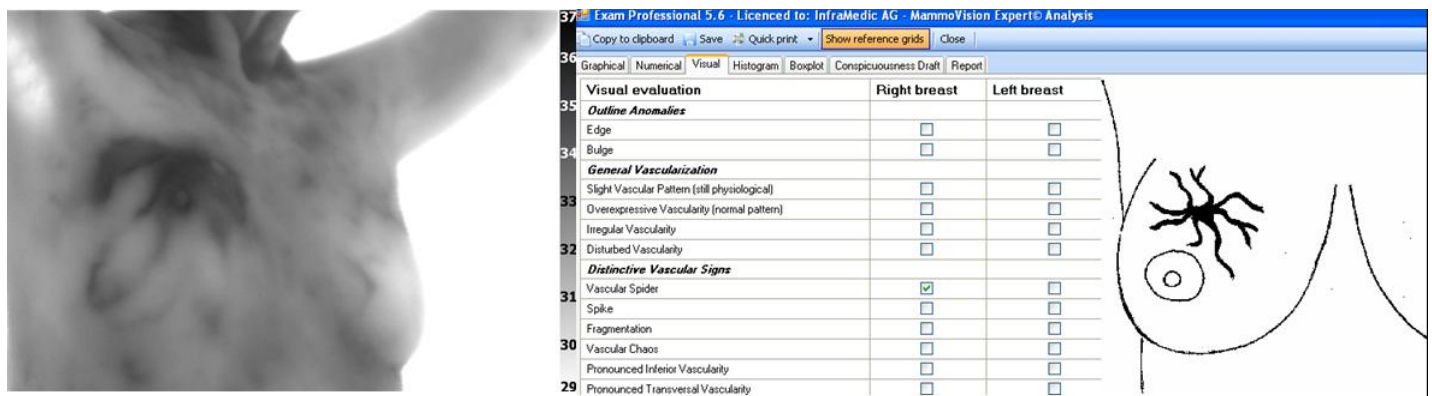


Figure 7: Grayscale masked MammoVision image for vascular description (left); MammoVision vascular description form (right)

According to the assessment criteria [24, 25] the results have been classified into 5 BIRAS groups (**B**reast **I**nfr**R**ed **A**ssessment **S**ystem):

BIRAS I: Inconspicuous; average lateral symmetry 0,5 °C or better; isothermia/homogeneous areas with temperatures in a range of 1,5 °C or less; no thermographically visible vascularity or few small vessels with homogeneous vessel characteristics including comparison with contra lateral breast; vascularity thermographically disappearing after cooling; no hot areas or hot spots, nipples and areola colder than the average of the breast, no bulge or edge signs, temperature decrease after cooling -0,5 °C or more

BIRAS II: Slightly conspicuous; fairly lateral symmetry between 0,5 and 1,0 °C; fairly isothermia/homogeneous areas with temperatures in a range between 1,5 and 3,0 °C; more impressive, but still physiological vessel characteristics, that can remain after cooling; nipples and areola colder than the average of the breast, no bulge or edge signs, temperature decrease after cooling -0,5 °C or more

BIRAS III: Conspicuous; often lateral asymmetry of more than 1,0 °C; thermal pattern of the breasts more inhomogeneous, isothermia/homogeneous areas with temperatures more than 3,0 °C differing; intensive and/or slightly abnormal vascular signs; slight edge or bulk signs; warm areas or warm spots; warm areola; most signs decreasing after cooling;

BIRAS IV: Very conspicuous; obvious lateral asymmetry of more than 1,5 °C; pronounced unmodified hot spots and hot areas; very inhomogeneous, isothermia/homogeneous areas with temperatures more than 4,5 °C differing; hot spikes; clear edge or bulk signs; areola and/or nipple hot; often one breast unilaterally affected, the other without or with less symptoms and signs; most signs resistive to cooling

BIRAS V: Significantly conspicuous; like BIRAS IV, impressive lateral asymmetry of more than 2,0 °C; cancer-related vascular signs (hot spiders, circular vessels, vascular chaos; very abnormal vascularity); paradoxical heating of spots or areas instead of temperature decrease due to cooling.

3 Patients examined

114 women were enrolled in the study at the breast center Prof. Schulte-Uebbing, Munich, who were asked and agreed to participate. All women have had an X-ray mammogram (MG) in a radiological institute within the same time period as the MammoVision had been performed, from January 2006 to June 2007. The reasons for the MG examinations differed: either for screening purposes, or a lump had been detected, or other symptoms were recorded. The age of the patients ranged between 29 and 69 years, with an average of 48,5 years. Based on the MG BI-RADS classification **B**reast **I**maging - **R**ating and **D**ata **S**ystem (American College of Radiology) the patients formed 5 groups, because MG is called the gold standard for breast cancer diagnosis. Group BI-RADS I n=41; group BI-RADS II n=45; group BI-RADS III n=15; group BI-RADS IV n=8; group BI-RADS V n=5; totally 114 women.

Most of the patients had additional ultrasonography (USG), some had MRI, in some women biopsies were examined.

4 Results

4.1 Illustrations of BIRAS classified results

The illustrations show women with typical signs and classifications before and after cooling, focused on the symptomatic breast. Figure 8 shows a woman with a typical BIRAS I result, completely inconspicuous, symmetrical thermal breast pattern, a small span of temperatures between minimum and maximum within each breast (isothermia) without thermographically visible vascularity.

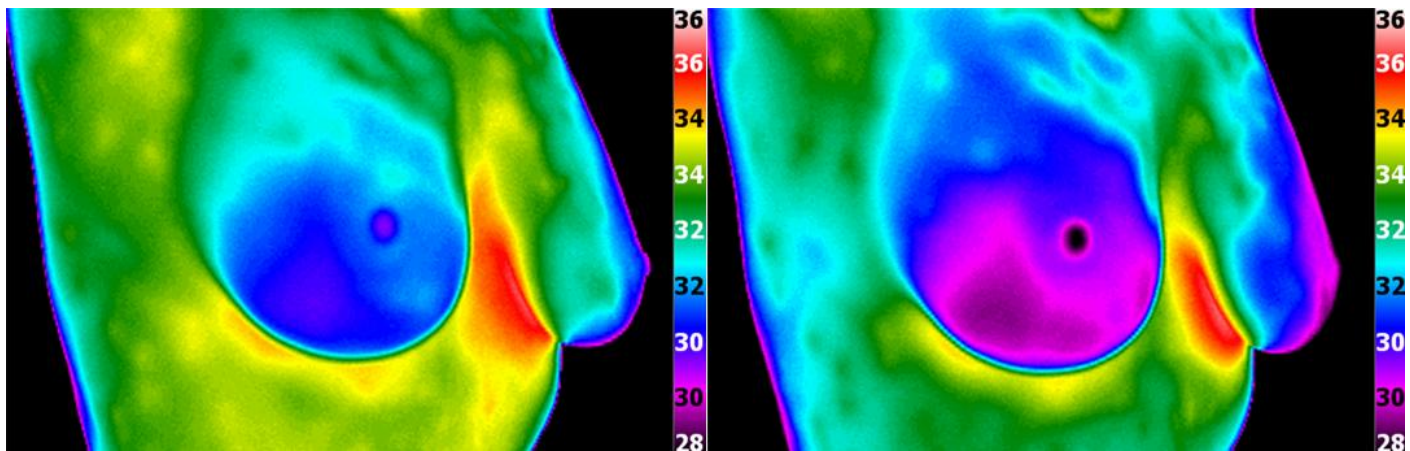


Figure 8: BIRAS I example; 29-year-old woman, left picture before cold stimulus, right picture after cold stimulus and cooling down; no clinical signs of breast disorder; in MammoVision very homogeneous, symmetrical thermal patterns, no vessels visible

Figure 9 represents a typical BIRAS II finding: still symmetrical, but with a broader range of temperatures within each breast (isothermia slightly affected), nipple cold, areola slightly warm, but cooling down after temperature decrease, warm vascular pattern above the breast that is sufficiently cooling down.

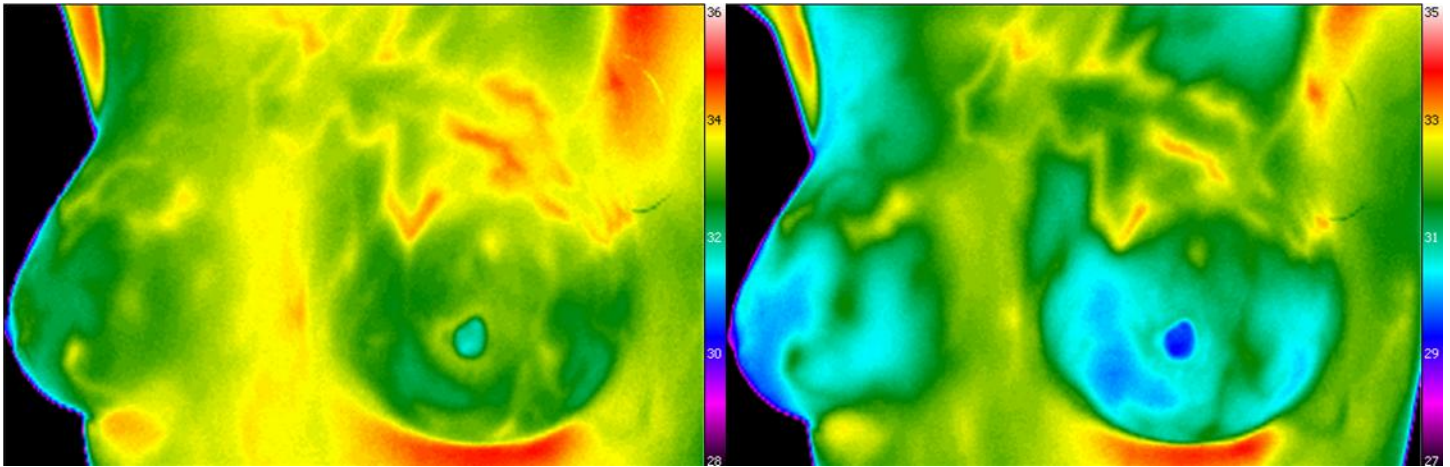


Figure 9: BIRAS II example; 42-year-old woman, left picture before cold stimulus, right picture after cold stimulus and cooling down; mastopathia, no other breast disease; MammoVision: symmetrical thermal pattern, areola and nipple cool, sufficient thermal down cold stimulus, small vessels that mostly disappear to be visible after cooling

Figure 10 is a good example for a BIRAS III result: especially the very warm periareolar areas on both breasts are suspicious and should give reason for further examinations; even after overall temperature decrease, the warm areolar region is visible.

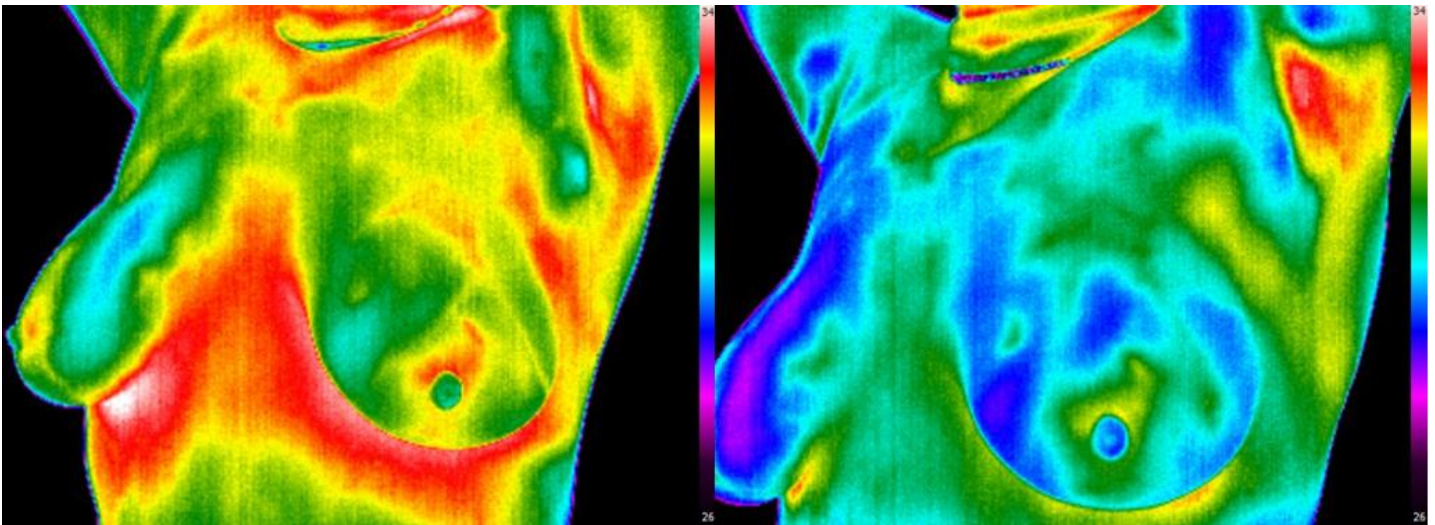


Figure 10: BIRAS III example; 43-year-old woman, left picture before cold stimulus and cooling down; mastopathia, palpable nodules. MammoVision: suspicious result, areolar heat both sides, intensive down cold stimulus

The woman presented in figure 11 shows a highly suspicious result. The thermal symmetry is lost, and the left breast seems clearly affected with heat signs. Impressively the areolar heat increases instead of cooling after the cooling stimulus. In the upper quadrants there are classified hot spot/hot areas signs, like an inflammation. This woman had a biopsy, and the result was an invasive ductal carcinoma (pT2 pN1, G3, ER +, PR +, HER -).

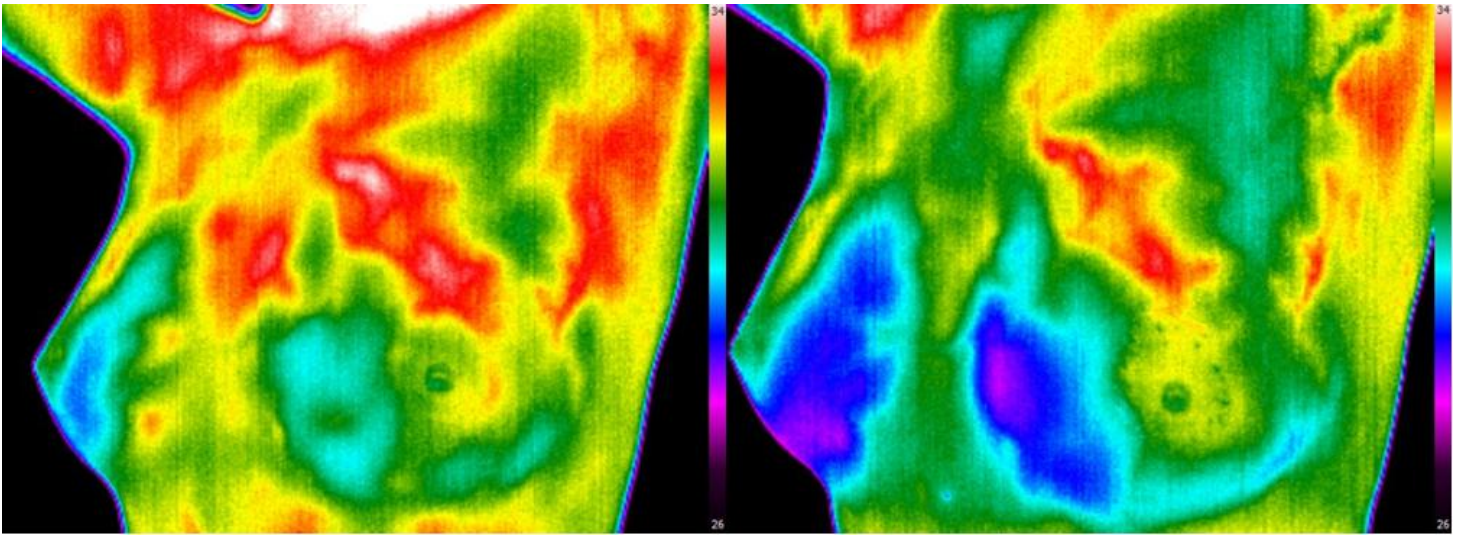


Figure 11: BIRAS IV example; 55 year old woman, left picture before cold stimulus, right picture after cold stimulus and cooling down; palpable lump in the left breast, questionable palpable axillary lymph nodes; MammoVision: very suspicious, highly asymmetrical, insufficient down cold stimulus, inflammatorious area above left areola; persisting heat even after cooling; biopsy invasive ductal carcinoma pT2 pN1, G3, ER +, PR +, HER –

Figure 12 shows a rare sign of malignancy in the right breast. The whole right breast is over heated compared to the left side; especially the vascular pattern is highly suspicious due to the circular vessel with aspects of a thermal vascular spider. Vascular abnormalities like this are highly conspicuous that there is already breast cancer. In this case it was an invasive ductal carcinoma; pT2 pN1, G3, ER +, PR +, HER +.

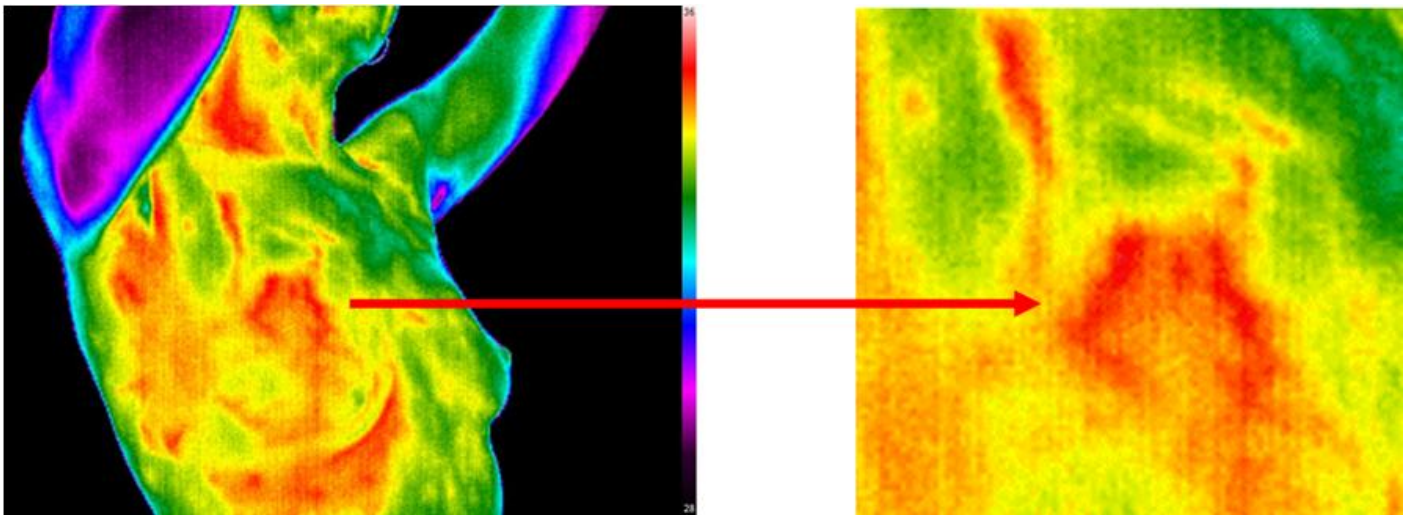


Figure 12: BIRAS V example; MammoVision very suspicious: extreme asymmetry, right breast heated intensively, absolute pathological vessel (circular structure with vascular spider aspects); biopsy: invasive ductal carcinoma; pT2 pN1, G3, ER +, PR +, HER +

4.2 Statistical results

All patients of the BI-RADS IV and V groups (highly suspicious to have breast cancer) have had clearly pathological signs in the MammoVision examination. The same holds true, with one exception, for the women of the BI-RADS III group. But in the BI-RADS I and II groups (not suspicious to have breast cancer) there were

remarkable differences between the MG classification and many of the MammoVision results. Especially in group BI-RADS II, half of the patients had slightly or very conspicuous thermal signs.

For a more detailed evaluation each BI-RADS group (I to V) was separately compared with the differentiated MammoVision results (BIRAS I to V) as presented in Figure 13. It can be stated that in the X-ray mammography BI-RADS I group the MammoVision findings mostly are classified as non conspicuous. In 9 of 41 women there were BIRAS II results to be found.

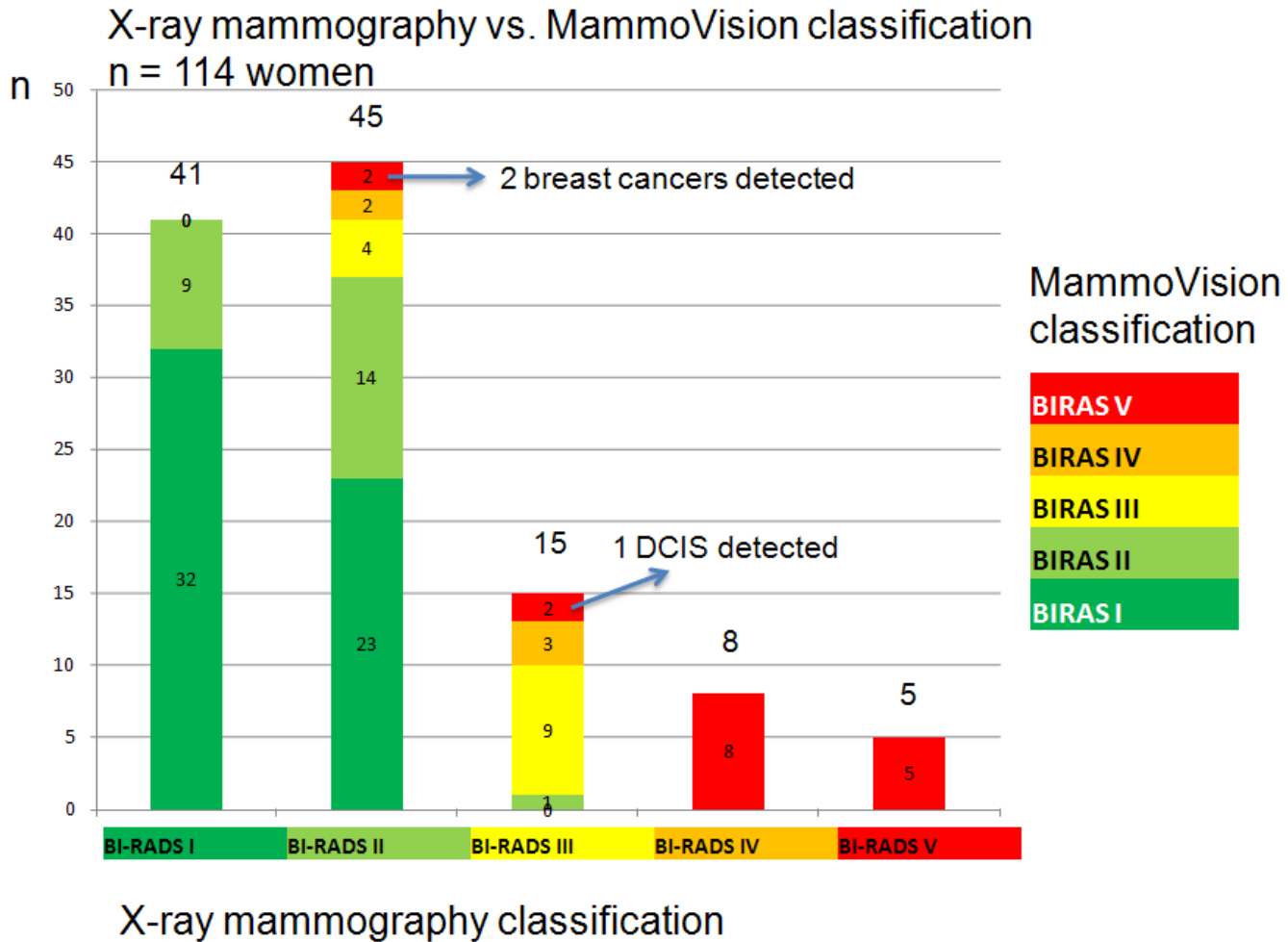


Figure 13: Comparison of X-ray mammography classification (BI-RADS I to V) versus MammoVision classification (BIRAS I to V)

The MG BI/RADS II group looked very inhomogeneous regarding the MammoVision results. About 50 % of the women had inconspicuous MammoVision findings, 30 % slightly suspicious results, but 8 of 45 women showed more conspicuous results, two of them classified as BIRAS IV and two as BIRAS V. They were therefore consequently examined by USG and MRI. Three of them had a biopsy, and in two of these women cancer was found.

Also in the BI-RADS III group, MammoVision gave the reason for additional USG, MG and MRI examinations. Two women underwent biopsy, one of them had DCIS.

5 Conclusion

The results of this study should be regarded as preliminary. The number of women included is too small to obtain statistically valid conclusions.

In the past only few studies have stressed the issue of comparing X-ray mammography to infrared thermography [26-29]. One problem of comparing infrared thermography to X-ray mammography is the amount of false positive and false negative results of MG. Even in this limited 114 women study, X-ray mammography failed to detect 2 cases of invasive breast cancer and one case of DCIS, whereas the MammoVision results gave reason for further examinations and at last for confirmation of these three cases of malignancy. Infrared thermography of the breast should therefore be compared to MRI (which actually is proving to be more accurate than MG) or to biopsy results. But MRI is expensive and rarely applied, and biopsy is invasive and only done in highly suspicious cases.

Regarding the future applications of breast thermography, this study wanted to contribute and to pinpoint the increased possibilities given by last generation high accuracy and reliable thermal measurement equipment. Further comparison and outcome research for infrared thermography of the breast is urgently needed.

6 Abbreviations

BI-RADS	Breast Imaging - Rating and Data System (American College of Radiology)
BIRAS	Breast InfraRed Assessment System
DCIS	Ductal Carcinoma in Situ
DGTR	Deutsche Gesellschaft fuer Thermographie und Regulationsmedizin (German Society of Thermography and Regulation Medicine)
ECG	Electrocardiography
EEG	Electroencephalography
IR	Infrared
LWIR	Long Wave Infrared
MG	(X-Ray) Mammography)
mK	Millikelvin
MRI	Magnetic Resonance Imaging
US FDA	United States Food and Drug Administration
USG	Ultrasonography

7 References

- [1] Lawson, R.N. and Chughtai, M.S., Breast cancer and body temperatures. *Can Med Assoc J* 88, 68-70, 1963
- [2] Lawson, R.N., Implications of surface temperature in the diagnosis of breast lesions. *Canad Med Assoc J* 75, 309, 1956
- [3] Lloyd Williams, K., Thermography in breast cancer. *Br J Radiol* 5, 75, 1969
- [4] Lloyd Williams, K., Lloyd Williams, F., Handley, R.S., Infrared thermometry in the diagnosis of breast diseases. *Lancet* 2, 1378, 1971
- [5] Lewis, J.D., Milbrath, J.R., Shaffer, K.A., Das Gupta, T.K., Implications of suspicious findings in breast cancer screening. *Arch Surg* 110, 903-907, 1975
- [6] Berz, R. and Sauer, H., The Medical Use of Infrared-Thermography History and Recent Applications. In: Deutsche Gesellschaft für Zerstörungsfreie Prüfung e.V. (Ed): *Thermografie-Kolloquium 2007. DGZfP-Berichtsband BB 107-CD*. Berlin 2007
- [7] Council Directive 92/42/EEC of 14 Jun 1993 on Medical Devices, 1993

- [8] Schwamm, E., Thermoregulation und Thermodiagnostik. In Rost, A., Thermographie und Thermoregulationsdiagnostik. Uelzen, 96-107, 1980
- [9] Heim, G., Thermographie im Zeitablauf unter verschiedenen Belastungsformen. In Rost, A., Thermographie und Thermoregulationsdiagnostik. MLV, Uelzen 64-73, 1980
- [10] Berz, R., Das Wärmebild und die Reaktion auf Abkühlung bei jungen gesunden Probanden. Ärztezeitschrift f Naturheilverfahren 26, 237-243, 1985
- [11] Berz, R., Regulation Thermography – a survey. In: Baleagas D, Busse G, Carlomagno CM, Wiecek B: Medical InfraRed Thermography MIRT'98. Technical University of Lodz, Poland, 1998
- [12] Berz, R., About Regulation Thermography - A Sensitive Tool for Early Diagnose and Therapy Control. Proceedings of the Focus Symposium on Health, Healing and Medicine, V 01 V. University of Windsor, Canada 1999
- [13] Berz, R., Infrared Regulation Imaging (IRI) – a different approach to health, wellness, and to prevention. ThermoMed 16, 49-58, 2000
- [14] Berz, R., Introducing Regulation into Infrared Imaging: ReguVision and MammoVision. In: Institute of Electronics, Technical University of Lodz (Ed): Proceedings of the 4th National Conference "Termografia i Termometria w Podczerwieni" TTP 2000. Lodz, Poland, 206-212, 2000
- [15] Berz, R., MammoVision - A New Approach to Diagnosis and Prevention of Breast Cancer. In: Benkö I, Kovaczicz I, Lovak I (Eds.): 12th Inter-national Conference on Thermal Engineering and Thermogrammetry (THERMO), June 2001, Budapest. Mate, Hungary, 265-272, 2001
- [16] Berz, R. and Sauer, H., Comparing effects of thermal regulation tests (cool air stimulus vs. cold water stress test) on infrared imaging of the female breast. In: Institute of Physics and Engineering in Medicine Ed), Clinical temperature measurement & thermography. York, UK, 36-41, 2007
- [17] Ring, E.F.J., Aarts, N.J.M., Black, C.M., Boesiger, P., Raynaud's phenomenon assessment by thermography. Thermology 3, 69-73, 1988
- [18] Ring, E.F.J., Cold stress test for the hands. In Ammer, K. and Ring, E.F.J., The thermal image in medicine and biology. Uhlen, Vienna, 237-240, 1995
- [19] Pascoe, D.D., Purohit, R.C., Shanley, L.A., Herrick, R.T., Pre- and post-operative evaluation of carpal tunnel syndrome. In Ammer, K. and Ring, E.F.J., The thermal image in medicine and biology. Uhlen, Vienna, 188-190, 1995
- [19] Berz R. and Bucher W., Procedure for the evaluation of thermographically images of a female or male breast (Verfahren zur Auswertung von Wärmebildern einer weiblichen oder männlichen Brust), German Patent Nr. 101 50 918, Munich, 2003
- [20] Medical Device Certification GmbH Stuttgart (Germany), CE-0483, 2007
- [21] Berz R., Equipment for measuring the temperature pattern at the body surface of a person (Vorrichtung zur Bestimmung der Temperaturverteilung an der Körperoberfläche einer Person), German Patent Nr. 199 56 346, Munich, 2004
- [23] Boesiger, P. and Stucki, D., Quantitative Auswertung und Interpretation von Infrarotthermogrammen der weiblichen Brust. In Lauth, G. and Eulenburg, R., Thermographie der weiblichen Brust. VCH, Weinheim, 185-219, 1986
- [24] Schulte-Uebbing, C., Breast Cancer and Heavy Metals, New Aspects for Diagnosis and Therapy, Oncology Meeting, Bad Aibling, Germany, February 2008

- [25] Schulte-Uebbing, C., Mammovision - ein komplementäres Mamma- Diagnostik- Verfahren, zaenmagazin 2 , 13 – 19, 2010
- [26] Parisky, Y.R., Sardi, A., Hamm, R., Hughes, K., Esserman, L., Rust, S., Callahan, K., Efficacy of computerized infrared imaging analysis to evaluate mammographically suspicious lesions. Am J Roentgenol 180, 263-269, 2003
- [27] Ng, E.Y.K., Ung, L.N., Ng, F.C., and Sim, L.S.J., Statistical analysis of healthy and malignant breast thermography, J Med Eng Tech, 25, 253–263, 2001.
- [28] Qi, H., Liu, Z.Q. and Wang, C., Breast cancer identification through shape analysis in thermal texture maps. Annual International Conference of the IEEE Engineering in Medicine and Biology Proceedings, 2, 1129 – 1130, 2002
- [29] Qi, H., Kuruganti, P.T., and Snyder, W.E., Detecting Breast Cancer from Thermal Infrared Images by Asymmetry Analysis. In: Diakides , N.A, Bronzino, J.D., Medical Infrared Imaging. CRC Press, Boca Raton, 11-1 – 11-13, 2008

